

Nodular Subcutaneous Phaeohyphomycosis due to *Medicopsis romeroi* in an Immunocompetent Patient

SMITA DESHKAR¹, NIRANJAN PATIL², ASHISH LAD³, SHRADDHA AMBERKAR⁴, SWATI SHARAN⁵



ABSTRACT

Fungal infections like subcutaneous phaeohyphomycosis are uncommon but are increasing lately, especially in tropical regions like India. Identification of correct aetiological agent is essential as different species can have different organ tropism. Here, a rare case of nodular subcutaneous phaeohyphomycosis in an immunocompetent 62-year-old male patient who developed nodule over right dorsum of foot is reported. After various diagnostic tests a rare dematiaceous fungus *Medicopsis romeroi* was identified as a causative agent in the nodular material by Internal Transcribed Spacer (ITS) sequencing. Surgical excision and antifungal therapy of itraconazole proved beneficial with no recurrence during a six months of follow-up. *Medicopsis romeroi* has been debated for its role in human infections however, it should be considered as one of the aetiological agents of subcutaneous phaeohyphomycosis.

Keywords: Fungal infection, Internal transcribed spacer sequencing, Itraconazole

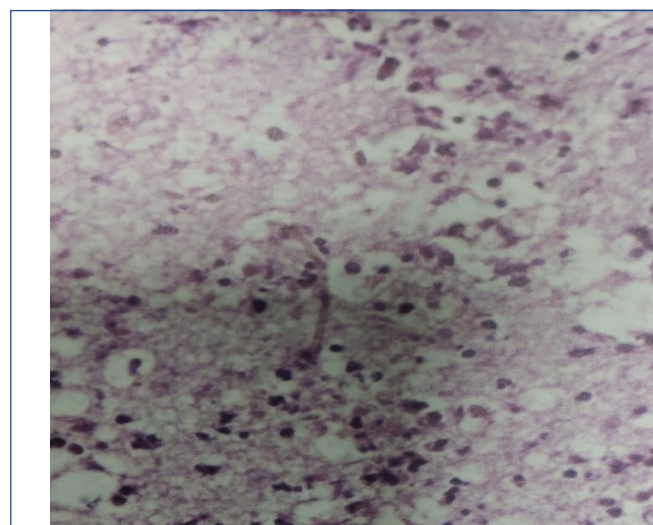
CASE REPORT

A 62-year-old male patient from western India was referred for swelling on dorsum of right foot since one year. The lesion had gradually progressed to a size of around 2 cm. No pain or itching was found. Patient was a farmer with history of frequent travels to hilly and forest regions. He had denied any history of injury, fever, chronic cough, weight loss, medication or any co-morbidity. On local examination, the subcutaneous lesion was skin coloured, solitary, firm, well defined, tender, non discharging, erythematous approximately 1.5×2 cm laterally on dorsum of right foot. There was no associated local lymphadenopathy. Systemic examination was unremarkable. X-ray of right foot revealed no bone involvement. Routine blood tests revealed raised Erythrocyte Sedimentation Rate (ESR) 29 mm/hour. Complete blood count showed slightly raised White Blood Cell (WBC) count 11,800/μL with neutrophilia (neutrophils 78%).

Surgical excision was performed and biopsy specimen was sent for aerobic and anaerobic bacterial culture sensitivity as well as fungal culture sensitivity testing. Gram stain smear showed only inflammatory cells but didn't show any bacteria or fungal elements. Primary smear with 40% KOH (Potassium Hydroxide) showed sparse fungal hyphae. Haematoxylin and Eosin (H&E) stained histopathological section revealed mixed inflammatory cells and pigmented fungal hyphae [Table/Fig-1]. Aerobic bacterial culture after 48 hours of incubation and anaerobic bacterial culture after five days of incubation did not yield any growth. A floccose gray white growth was observed on Sabouraud's Dextrose Agar (SDA) with dark reverse after 14 days of incubation and colour darkened after a week [Table/Fig-2]. The Lactophenol Cotton Blue (LPCB) mount revealed dematiaceous (brown), broad septate branching hyphae with scanty spores [Table/Fig-3]. The grown fungus could not be identified by Matrix-Assisted Laser Desorption/Ionisation-Time of Flight Mass Spectrometry (MALDI TO MS) and was then subjected to molecular identification.

Molecular identification of the isolated fungus was done by Panfungal DNA Polymerase Chain Reaction (PCR) and sequencing. The ITS regions (ITS1 and ITS2) and the ribosomal DNA (rDNA) genes (18S, 28S and 5.8S) were amplified by PCR using extracted DNA. The purified product was sequenced on ABI 3500 DX analyser. The sequences were then run through GenBank Basic Local Alignment Search Tool (BLAST) searches (<http://www.ncbi.nlm.nih.gov/BLAST/Blast.cgi>)

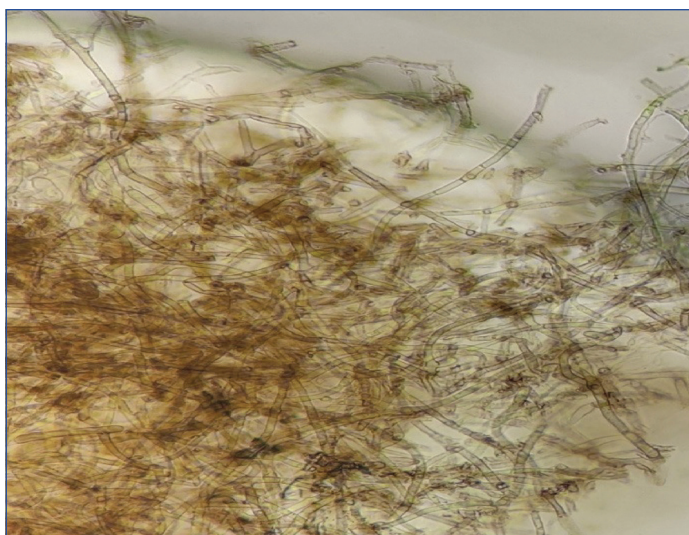
for species identification. BLAST searches confirmed the isolate as *Medicopsis romeroi* with gene accession no. MW301048.1.



[Table/Fig-1]: Mixed inflammatory cells and pigmented fungal hyphae on Haematoxylin and Eosin-stain 40X.



[Table/Fig-2]: White gray floccose colonies of *M. romeroi* on Sabouraud's dextrose agar (SDA).



[Table/Fig-3]: Dark brown coloured, broad, septate and branched hyphae of *M. romeroi* seen in LPCB (40X).

Anti-Fungal Susceptibility Testing (AFST) of the isolate by broth microdilution method was done however, it gave inconclusive results. Patient was treated empirically with itraconazole given 200 mg/day for 21 days. Follow-up on day 30 and on day 60 postsurgical excision showed no swelling, no recurrence. Follow-up upto six months was uneventful. Informed consent was obtained from the patient.

DISCUSSION

Subcutaneous phaeohyphomycosis is a rare entity but incidence and diversity of causative agents of phaeohyphomycosis have been increasing globally. It is common in tropical climatic regions of the world [1]. The subcutaneous infections appear on extremities. The inoculation and infection usually take place when there is trauma to skin and subcutaneous tissue [2]. In this case, patient presented with a solitary nodule on dorsum of right foot. Though he denied history of injury to leg, there might be a trivial injury during his visits to the farms/hilly forest regions which went unnoticed and later developed into lesion. There are many aetiological agents associated with subcutaneous phaeohyphomycosis including *Exophiala* spp., *Phialophora* spp., *Phaeoacremonium* spp., *Pleurostomophora* spp., *Bipolaris* spp., *Alternaria* spp. [3]. In this case, *Medicopsis romeroi* was found be causative fungi while presenting as subcutaneous phaeohyphomycosis unlike its known disease mycetoma. These saprophytic fungi are found commonly in soil and plants. *Medicopsis* infection is prevalent in immunocompromised patients either due to chemotherapy, post-

transplant immunosuppression or immunomodulatory drugs. It is also reported in patients with uncontrolled diabetes mellitus type 1/2 [4]. Few cases are reported in literature where *Medicopsis* and phaeohyphomycosis are implicated in immunocompetent individuals like present case [Table/Fig-4] [1,4-8]. Melanin is the virulence factor proposed to be responsible for pathogenic potential of dematiaceous fungi even in immunocompetent people. It acts by scavenging free radicals produced by phagocytic cells in the oxidative process and also helps in penetration of fungi into the host cell [2].

Medicopsis colonies are greyish, velvety with broad hyphae like other dematiaceous fungi and hence difficult to identify. It can be identified microscopically by pycnidia, the asexual fruiting bodies but these appear, if at all, only after prolonged incubation [9]. The genus of *Medicopsis* was given to pyrenochaeta based on a phylogenetic study in 2006 [10]. Early, rapid and accurate identification of pathogenic fungi is important in order to guide the selection of appropriate antifungal therapy and thus to improve patient's outcome. Without treatment, infection may invade skeletal system eventually needing debridement/amputation [6]. MALDI TOF was unable to identify *Medicopsis* in present case. However, one study by Fraser M et al., successfully identified eumycetoma agents and related fungi using MALDI-TOF MS [11]. Molecular methods using sequencing of ITS and the D1/D2 regions of rDNA for identifying non sporulating fungi till species level was first done by Santos DW et al., in Brazil [12].

The present case could appreciate hyphae without sporulation however; identification was done only by sequencing. This non sporulation affects AFST. The AFST guidelines are also limited as only few cases are reported till now [1,4-8]. Due to this, epidemiological cut-offs or clinical breakpoints are not established yet. A study of 2016 has shown variable Minimum Inhibitory Concentration (MIC) for amphotericin B and itraconazole, Low MICs for voriconazole and higher for fluconazole and ketoconazole [13]. Main treatment protocol remains surgical excision of subcutaneous lesion followed by antifungal therapy to prevent further systemic invasion by *Medicopsis romeroi* as seen in [Table/Fig-4]. Identification of fungal infections may be tricky at times as unusual isolates may neither present typically nor give characteristic morphology or sporulating structures which might help in identification. In this case, authors did not find any pycnidia and MALDI TOF could not give identification. So, ITS based pan fungal PCR and sequencing had to use for species level identification, emphasising importance of newer modalities for identification of unusual fungus like *Medicopsis romeroi*.

Sr. No.	Study	Age/Gender	Clinical presentation	Immune status	Diagnosis	Treatment	Outcome
1	Prasad S et al., (2020) [6]	27/F	Lesion on left thigh	Long term steroid use	ITS sequencing	Surgical excision and debridement	NA
2	Jeddi F et al., (2020) [7]	30/M	Lesion on right hallux	Immunosuppressors post kidney transplant	ITS sequencing	Surgical excision and antifungals	No recurrence at six months
3	Chanyachailert P et al., (2019) [4]	80/M	Lesion on right foot	Uncontrolled diabetes mellitus	ITS sequencing	Surgical excision	Cured at nine months
4	Sharma B et al., (2017) [8]	48/M	Lesion on left foot	Immunosuppressive drugs for leprosy and diabetes	ITS sequencing	Surgical excision and Itraconazole	Lost to follow-up at Day 15.
5	Abdolrasouli A et al., (2016) [1]	88/M	Lesion on dorsum of right hand	Long term steroid use	ITS sequencing	Surgical excision and debridement	NA
6	Babu K et al., (2014) [5]	25/F	Chronic endophthalmitis of left eye	Immunocompetent	NA (Reference lab)	Surgery and intravitreal Amphotericin B and Voriconazole	No recurrence at six months
7.	Present case (2021)	62/M	Lesion on dorsum of right foot	Immunocompetent	ITS sequencing	Surgical excision and Itraconazole	No recurrence at six months

[Table/Fig-4]: Table shows various studies with lesions due to *Medicopsis romeroi* and their management [1,4-8].

M: Male; F: Female; ITS: Internal transcribed spacer; NA: Not available

CONCLUSION(S)

Medicopsis romeroi should be considered as cause of cutaneous/subcutaneous lesions especially in tropical regions even in immunocompetent individuals. Conventional methods of fungal identification are insufficient for the emerging rare pathogenic fungi like *Medicopsis romeroi*. Molecular methods provide sensitive and specific diagnosis of viable and non viable fungal pathogens in a variety of clinical specimens.

REFERENCES

- [1] Abdolrasouli A, Gonzalo X, Jatan A, McArthur GJ, Francis N, Azadian BS, et al. Subcutaneous phaeohyphomycosis cyst associated with *Medicopsis romeroi* in an immunocompromised host. *Mycopathologia*. 2016;181(9):717-21.
- [2] Chintagunta S, Arakkal G, Damarla S, Vodapalli A. Subcutaneous phaeohyphomycosis in an immunocompetent individual: A case report. *Indian Dermatol Online J*. 2017;8(1):29-31.
- [3] Walsh T, Hayden R, Larone D. Larone's Medically Important Fungi A guide to identification. 6th ed. New York, Washington DC: ASM Press. 2018.
- [4] Chanyachailert P, Leeyaphan C, Bunyaratavej S, Chongtrakool P. Subcutaneous phaeohyphomycosis from *Medicopsis romeroi* in a diabetic patient. *Medical Mycology Case Reports*. 2019;26:69-72.
- [5] Babu K, Murthy PR, Prakash PY, Kattige J, Rangaswamy S, Murthy VR, et al. Chronic endophthalmitis due to *Pyrenochaeta romeroi* in an immunocompetent host—A case report from Southern India. *Retinal Cases & Brief Reports*. 2014;8(3):197-99.
- [6] Prasad S, Khurana U, Karuna T, Brahmachari S, Sinha JK, Tandon A, et al. Fine needle aspiration of nodular cystic swelling showing a rare melanized fungus *Medicopsis romeroi*: A case report. *Diagnostic Cytopathology*. 2020;01-04.
- [7] Jeddi F, Paugam C, Hartuis S, Denis-Musquer M, Sabou M, Lavergne RA, et al. *Medicopsis romeroi* nodular subcutaneous infection in a kidney transplant recipient. *Int J Infect Dis*. 2020;95:262-64.
- [8] Sharma B, Singh P, Pandey K, Mittal G, Ramesh V, Deb M. Subcutaneous cyst due to *Medicopsis romeroi* in a diabetic Lepromatous Leprosy patient: An interesting case report and review from India. *J Clin Diag Res*. 2017;11(10):DD01-03.
- [9] Dinh A, Levy B, Bouchand F, Davido B, Duran C, Cristi M, et al. Subcutaneous phaeohyphomycosis due to *Pyrenochaeta romeroi* mimicking a synovial cyst. *Frontiers in Microbiology*. 2016;7:1405.
- [10] de Gruyter J, Aveskamp MM, Woudenberg JHC, Verkley GJM, Groenewald JZ, Crous PW. Molecular phylogeny of *Phoma* and allied anamorph genera: Towards a reclassification of the *Phoma* complex. *Mycol Res*. 2009;113:508-19.
- [11] Fraser M, Borman AM, Johnson EM. Rapid and Robust Identification of the Agents of black-grain mycetoma by matrix-assisted laser desorption/ionization-time of flight mass spectrometry. *J Clin Microbiol*. 2017;55(8):2521-28.
- [12] Santos DW, Padovan AC, Melo AS, Gonçalves SS, Azevedo VR, Ogawa MM, et al. Molecular identification of melanised non-sporulating moulds: A useful tool for studying the epidemiology of phaeohyphomycosis. *Mycopathologia*. 2013;175(5-6):445-54.
- [13] Borman AM, Desnos-Ollivier M, Campbell CK, Bridge PD, Dannaoui E, Johnson EM. Novel taxa associated with human fungal black-grain mycetomas: *Emarellia grisea* gen. nov., sp. nov., and *Emarellia paragrisea* sp. nov. *J Clin Microbiol*. 2016;54(7):1738-45.

PARTICULARS OF CONTRIBUTORS:

1. Microbiologist, Department of Microbiology and Molecular Biology, Metropolis Healthcare Limited, Mumbai, Maharashtra, India.
2. Head, Department of Microbiology and Molecular Biology, Metropolis Healthcare Limited, Mumbai, Maharashtra, India.
3. Senior Laboratory Manager, Department of Microbiology and Molecular Biology, Metropolis Healthcare Limited, Mumbai, Maharashtra, India.
4. Section Head, Department of Microbiology, Metropolis Healthcare Limited, Mumbai, Maharashtra, India.
5. Senior Scientific Officer, Department of Molecular Biology, Metropolis Healthcare Limited, Mumbai, Maharashtra, India.

NAME, ADDRESS, E-MAIL ID OF THE CORRESPONDING AUTHOR:

Dr. Smita Deshkar,
Metropolis Healthcare Limited, Kohinoor City, Commercial Bldg-A, 4th Floor,
Off-L.B.S Road, Vidyavihar (West), Mumbai-400070, Maharashtra, India.
E-mail: smitadeshkar@gmail.com

PLAGIARISM CHECKING METHODS: [Jain H et al.]

- Plagiarism X-checker: May 05, 2021
- Manual Googling: Jun 22, 2021
- iThenticate Software: Jul 16, 2021 (9%)

ETYMOLOGY: Author Origin

AUTHOR DECLARATION:

- Financial or Other Competing Interests: None
- Was informed consent obtained from the subjects involved in the study? Yes
- For any images presented appropriate consent has been obtained from the subjects. No

Date of Submission: **May 04, 2021**

Date of Peer Review: **May 28, 2021**

Date of Acceptance: **Jun 25, 2021**

Date of Publishing: **Aug 01, 2021**